


Corneal Microbes: Differentiating Bacteria, Fungi, Parasites, and Viruses



COA Monterey Symposium 2017

Nicholas Colatrella, OD, FAAO, Dipl AAO, ABO, ABCMO
Jeffrey R. Varanelli, OD, FAAO, Dipl ABO, ABCMO

Disclosures

- Allergan Pharmaceuticals Speaker's Bureau
- Bio-Tissue
- BioDLogics, LLC
- Katena/IOP
- Seed Biotech
- Johnson and Johnson Vision Care, Inc.
- Shire Pharmaceuticals

• Nicholas Colatrella, OD, FAAO, Dipl AAO, ABO, ABCMO

• Jeffrey Varanelli, OD, FAAO, Dipl ABO, ABCMO



Introduction

- Microbial Keratitis is an infectious corneal ulcer, that is due to the proliferation of microorganisms, that creates associated inflammation and tissue destruction
 - includes bacteria, fungi, viruses, and parasites
- This is a potentially sight-threatening condition and frequently presents as an ocular emergency
 - True ocular emergency due to potential for rapid progression
- Can be quite challenging to distinguish the different types of microbes, or even distinguishing it from other noninfectious or inflammatory corneal conditions resulting from trauma or immune-mediated reactions

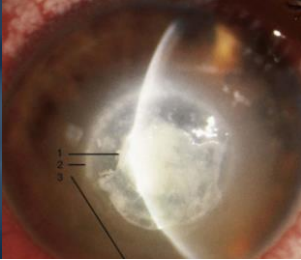
Introduction

- It is estimated that 30,000 cases of microbial keratitis occur in the USA annually
- With 10 to 30 individuals per 100,000 contact lens wearers developing microbial keratitis annually in the USA
- Costing \$225 million in annual expenditures for medical care of these conditions

Introduction

- Intent of today's lecture
 - Review common causes of microbial infections
 - Increase your "Suspicion of index" when dealing with MK
 - Give a tidbit or two of new information
 - Become a resource for future studies
 - And of course.....Quiz you

Poll Question • Name all the microbes that can cause Ring infiltrates



Your poll will show here

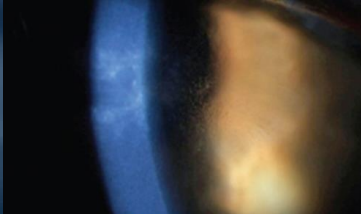
1 2

Install the app from pollev.com/app Make sure you are in Slide Show mode

Still not working? Get help at pollev.com/app/help or Open poll in your web browser

Poll Question

• Name the microbes that can cause Radial Perineuritis



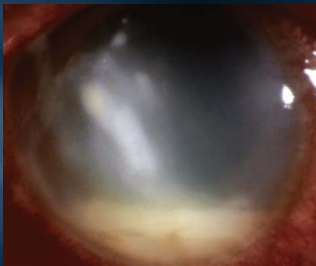
Your poll will show here

1 2

Install the app from pollev.com/app Make sure you are in Slide Show mode

Still not working? Get help at pollev.com/app/help or Open poll in your web browser

Poll Question • Name all the types of Bacteria that cause rapid tissue destruction



Your poll will show here

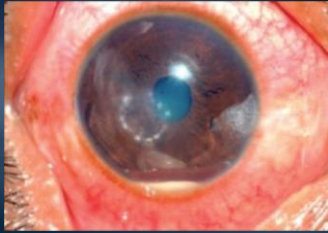1 2

Install the app from pollev.com/app Make sure you are in Slide Show mode

Still not working? Get help at pollev.com/app/help or Open poll in your web browser

Poll Question

1. Which microbe creates a Wreath like configuration to the cornea?



- A. Pseudomonas
- B. Nocardia
- C. Non-Tuberculosis Mycobacterium
- D. Fungal Infections
- E. Infectious Crystalline Keratopathy

Your poll will show here

1

Install the app from
pollev.com/app

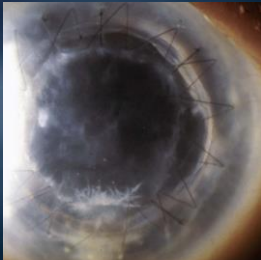2

Make sure you are in
Slide Show mode

Still not working? Get help at pollev.com/app/help
or
Open poll in your web browser

Poll Question

2. Which microbe creates a Snow flake arborizing (branching) pattern?



- A. Pseudomonas
- B. Nocardia
- C. Non-Tuberculosis Mycobacterium
- D. Fungal Infections
- E. Infectious Crystalline Keratopathy

Your poll will show here

1

Install the app from
pollev.com/app

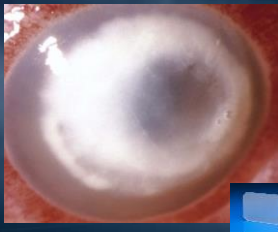2

Make sure you are in
Slide Show mode

Still not working? Get help at pollev.com/app/help
or
Open poll in your web browser

Poll Question

3. Which microbe creates a Ground glass appearance to cornea?



- A. Pseudomonas
- B. Nocardia
- C. Non-Tuberculosis Mycobacterium
- D. Fungal Infections
- E. Infectious Crystalline Keratopathy

Your poll will show here

1

Install the app from
pollev.com/app

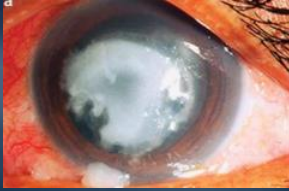2

Make sure you are in
Slide Show mode

Still not working? Get help at pollev.com/app/help
or
Open poll in your web browser

Poll Question

4. Which microbe creates a dry rough appearance to the cornea?



- A. Pseudomonas
- B. Nocardia
- C. Non-Tuberculosis Mycobacterium
- D. Fungal Infections
- E. Infectious Crystalline Keratopathy

Your poll will show here

1

Install the app from
pollev.com/app

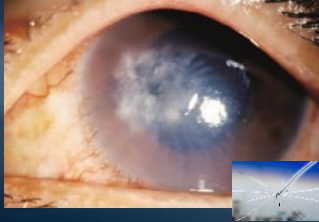
2

Make sure you are in
Slide Show mode

Still not working? Get help at pollev.com/app/help
or
[Open poll in your web browser](#)

Poll Question

5. Which microbe creates a Cracked windshield appearance to the cornea?



- A. Pseudomonas
- B. Nocardia
- C. Non-Tuberculosis Mycobacterium
- D. Fungal Infections
- E. Infectious Crystalline Keratopathy

Your poll will show here

1

Install the app from
pollev.com/app

2

Make sure you are in
Slide Show mode

Still not working? Get help at pollev.com/app/help
or
[Open poll in your web browser](#)

Bacterial Keratitis

Bacterial Keratitis

- Bacterial keratitis is a leading cause of corneal blindness in developing nations, usually caused by ocular trauma
- Statistics from the Eye Bank Association of America demonstrate that approximately 1% of all corneal transplants are performed as a result of microbial keratitis
- Based upon the annual incidence of bacterial keratitis, it is estimated that approximately 0.5–1% of infectious keratitis cases require surgical intervention in the USA

Bacterial Keratitis

- Bacterial keratitis is the most common cause of suppurative corneal ulceration, which rarely occurs in the normal eye because of the human cornea's natural resistance to infection
- Predisposing factors alter the defense mechanisms of the ocular surface and permit bacteria to invade the cornea
 - including contact lens wear, trauma, ocular surface disease, corneal surgery, systemic diseases, immunosuppression
- There are no specific clinical signs to help confirm a definite bacterial cause in microbial keratitis
 - Identify the risk factors for ocular infection
 - Assess the distinctive corneal findings
- When there is strong suspicion for a possible infectious keratitis, laboratory investigations should be considered in order to identify and confirm the causal organisms

Bacterial Keratitis

- Based on the clinical and laboratory findings, a therapeutic plan can then be initiated. It is sometimes necessary to modify the therapeutic plan based on clinical response and tolerance of the antimicrobial agents
- The goals for treating bacterial keratitis are to treat the corneal infection and associated inflammation, and to restore corneal integrity and visual function
- Medical therapy with appropriate antibiotics is the mainstay of treatment
- The outcome usually depends on the preceding pathology and the extent of ulceration at the time of presentation
- Surgery may be considered if medical therapy fails to eradicate the pathogens or if the vision is markedly threatened by the infection or resultant scar

Host Defense

- Bacterial keratitis usually occurs in patients with predisposing factors, which can compromise normal ocular surface defenses
- These natural defenses include:
 - Eyelid
 - Blink reflex
 - Tear film
 - Antimicrobial properties
 - Corneal epithelium
 - Mucin on surface
 - Normal ocular flora

Name the Bacteria that can penetrate an intact corneal epithelium

Start the presentation to activate live content
If you see this message in presentation mode, install the add-in or get help at Pillbox.com/app

Host Defense

- An intact corneal epithelium is an important defense factor
 - Typical sources of bacterial keratitis (i.e., Staphylococci, Streptococci and Pseudomonas) all require some compromise to the epithelium, and adhere to the edges of the defect
- Only a few bacteria can penetrate an intact corneal epithelium:
 - Canadian National Hockey League
 - Corynebacterium diphtheria
 - Neisseria gonorrhoeae / Meningitides
 - Haemophilus aegyptius
 - Listeria monocytogenes
- Compromised corneal epithelial integrity caused by contact lens wear, corneal trauma, or corneal surgery are the most common predisposing factor to bacterial ulcers
- Others include bullous corneal edema, absence of corneal sensation from herpetic corneal infection or topical anesthetic abuse, and local immunosuppression from prolonged use of topical corticosteroids

Pathogenesis

- Bacterial keratitis can be caused by multiple microorganisms
 - Staphylococci (Staph Aureus and Coagulase-Negative Staphylococci) and Pseudomonas are the most common organisms in the USA
- Streptococcus pneumoniae, however is the most predominant cause of bacterial keratitis in developing nations and most common worldwide
- Animal models show number of organisms needed to create bacterial keratitis:
 - 50 P. aeruginosa
 - 100 Staphylococcus aureus

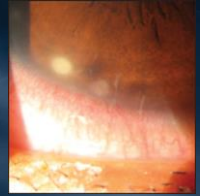
Pathogenesis

Sequence of bacterial infection:

1. Adherence
 - * Shortly after injury, viable bacteria adhere to the damaged edges of corneal epithelial cells and to the basement membrane or the bare stroma near the wound edge
 2. Invasion
 - * Bacterial invasion into surface epithelial cells
 - * mediated by the interactions between the bacterial cell-surface proteins, integrins, epithelial cell-surface proteins, and the release of proteases by bacteria
 3. Colonization
 - * bacteria continue to replicate in the corneal stroma
- * The largest increase in a bacterial population occurs within the first 2 days of stromal infection
 - * Viable bacteria tend to be found at the peripheral margins of the infiltrate or deep within a central ulcer crater. Unchecked bacterial multiplication in the corneal stroma results in progressive enlargement or extension of infectious foci into the surrounding cornea

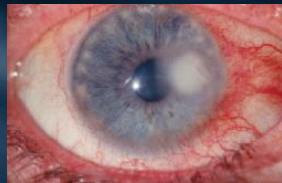Corneal inflammation and Tissue damage

- * Recruitment of acute inflammatory cells occurs within a few hours after bacterial inoculation
- * As neutrophils accumulate, cytokines (leukotrienes) and complement components are released, attracting polymorphonuclear leukocytes (PMN's), which create an infiltrate
- * Macrophages subsequently begin to migrate to the cornea to ingest invading bacteria and degenerating neutrophils



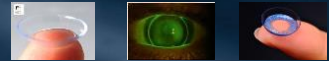Corneal inflammation and Tissue damage

- * PMN's phagocytize and digest the bacteria, but also damage stromal tissue by releasing numerous collagenolytic enzymes that directly degrade stromal tissue
- * Extensive stromal inflammation eventually leads to proteolytic stromal degradation and liquefactive tissue necrosis



Contact Lens Use

- * Contact lens wear is an increasingly popular method for vision correction
 - * 32.0 Million in 2002
 - * 40.9 Million in 2014
- * Contact lens wear has been identified as the most common risk factor for bacterial keratitis in developed countries
- * All types of contact lenses, including hard, gas-permeable, soft, disposable, and cosmetic lenses, have been implicated in microbial keratitis



Contact Lens Use

- * On average, contact lens users have a 1.5% chance of developing infectious keratitis during a lifetime of contact lens wear (1989-2002).
 - * The incidence for rigid gas-permeable lenses is 0.4 to 4 per 10 000
 - * The incidence for DW SCL is 2.7 to 4.1 per 10 000
 - * The incidence for EW SC is 9.3 to 20.9 per 10 000
 - * Continuous lens wear increases the risk of infectious keratitis by approximately tenfold, and the risk of infection is enhanced incrementally with each consecutive night of lens wear.
- * More recent literature suggests 2 trends:
 1. CL Ulcers are increasing in severity /becoming more sight threatening
 - * 45.7% size >4mm
 - * 36.3% hypopyon
 - * 46.4% central or paracentral location
 2. Ulcers in daily disposables were less severe, and resulted in better outcomes
- * Burden of CL related infectious keratitis annually:
 - * 1 million doctor's office and outpatient clinic visits
 - * 58,000 emergency room visits
 - * 175 million in direct healthcare expenditures

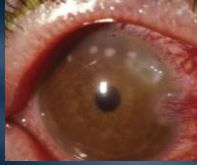Yildiz EH, Ariani S, Hammersmith KM, et al. Trends in contact lens-related corneal ulcers at a tertiary referral center. *Cornea*. 2012; 31:1307-1310.

Contact Lens Use

- * Bacteria are largely responsible for the majority of CL related infections
 - * *Pseudomonas* spp. is the most common isolate
 - * *Serratia Marcescens* is as common in FL
 - * Smaller subset due to fungal or protozoal infections
- * Bacteria can adhere to a contact lens regardless of lens materials and microbes can survive in the moist chamber of a contact lens case
- * Worn contact lenses with surface protein and mucin deposits or irregularities are more susceptible to bacterial adhesion
 - * The polysaccharide layer of encapsulated bacteria can facilitate colonization of the contact lens surface
- * A biofilm can protect bacteria from antibacterial agents. Extended wear contact lenses augment the risks of infection by accumulating coatings or debris under the lens and by enhancing bacterial colonization on the cornea

Staphylococci

- *Staphylococcus*, the most common Gram + Cocci
 - Coagulase positive staphylococcus
 - *Staphylococcus Aureus*
 - Coagulase negative staphylococcus
 - *Staphylococcus epidermidis*
- Dominant organisms of the normal ocular and periocular flora
- Produces:
 - rapidly progressive infiltrate
 - round or oval with dense infiltration and a distinct border
 - moderate anterior chamber reaction
 - endothelial plaques
 - Hypopyon (sterile)

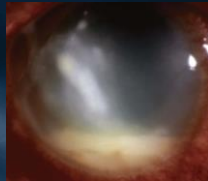


Staphylococci

- Methicillin-resistant *Staphylococcus aureus* (MRSA) and Methicillin-resistant *Staphylococcus epidermidis* (MRSE)— has been isolated with increasing frequency
 - MRSA now the most common infection post LASIK (2005)
- Methicillin is no longer used as an antibiotic
 - strains exhibit resistance to a number of other, conventional antibiotics
- Community-acquired variant of MRSA (CA-MRSA) exhibits less resistance than hospital acquired disease
 - With greater virulence profile

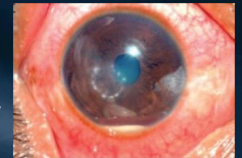Streptococci

- *Streptococcus pneumoniae*
 - Gram + Cocci
- **Most common cause of bacterial keratitis worldwide**
- keratitis usually occurs after corneal trauma, dacryocystitis, or filtering bleb infection.
- The ulcer tends to be:
 - acute, purulent, and rapidly progressive with a deep stromal abscess
- The anterior chamber reaction is usually severe with marked hypopyon and retrocorneal fibrin coagulation.
- Perforation secondary to ulcer is common.



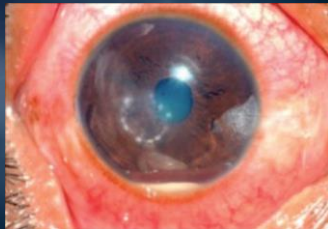Nocardia

- *Nocardia asteroides* grow slowly
 - Gram + bacillus
- branching filaments
- Produces indolent ulcer after minor trauma, particularly with exposure to contaminated soil (widespread distribution in soil).
- The keratitis usually waxes and wanes.
- The characteristic features of *Nocardia* keratitis include raised, superficial pinhead-like infiltrates in a wreathlike configuration, brush fire border appearance, and multifocal or satellite lesions
- Tx w Topical fortified Amikacin
- SCUT found steroids worsen



Poll Question

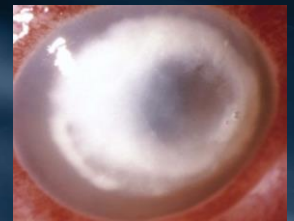
1. Which microbe creates a Wreath like configuration to cornea



- A. *Pseudomonas*
- B. *Nocardia*
- C. Non-Tuberculosis Mycobacterium
- D. Fungal Infections
- E. Infectious Crystalline Keratopathy

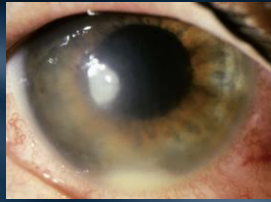
Pseudomonas

- Most common Gram-negative Rod pathogen
- largely associated with the use of soft contact lenses
- Rapid progression, dense stromal infiltrate, marked suppuration, liquefactive necrosis, and descemetocoele formation or corneal perforation (72 hours)
- remaining uninvolved cornea usually has a ground-glass appearance and diffuse graying of epithelium
- Worse in tropical warm settings
- Emits a sweet odor and can appear soupy
- Virulence from both proteases and exotoxins it produces



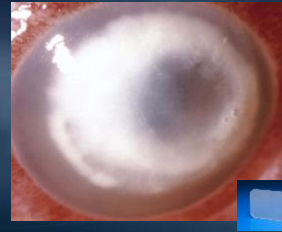
Pseudomonas

- Despite appropriate treatment, the keratitis may progress rapidly into a deep stromal abscess and stromal keratolysis with perforation may occur
- Similar to Acanthamoeba:
 - Can have a corneal ring infiltrate
 - Can create radial perineuritis
- Can have multiple elevated granular opacities caused by less virulent species with a more indolent course



Poll Question

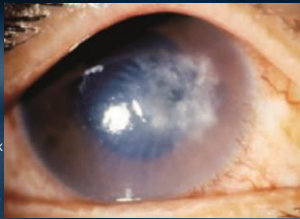
3. Which microbe creates a Ground glass appearance to cornea?



- A. Pseudomonas
- B. Nocardia
- C. Non-Tuberculosis Mycobacterium
- D. Fungal Infections
- E. Infectious Crystalline Keratopathy

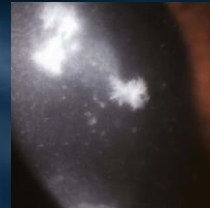
Nontuberculous Mycobacteria

- Gram + bacillus, Acid fast Mycobacteria
- Previously known as atypical mycobacteria
- The most common pathogens are:
 - Mycobacterium fortuitum
 - M. chelonae
- found in soil and water
 - Normal flora of skin, sputum and gastric
- cause a slowly progressive keratitis
- Occur after:
 - corneal foreign body
 - corneal trauma
 - following corneal surgery, particularly after LASIK
- Creates focal areas of stromal necrosis Anterior and posteriorly
- associated with delayed onset of symptoms, and severe ocular pain can develop from 2 to 8 weeks after exposure to the organism.



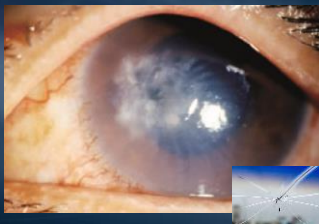
Nontuberculous Mycobacteria

- Infiltrates are typically nonsuppurative and can be solitary or multifocal, with variable anterior chamber reactions.
- A 'cracked windshield' appearance has been described which may aid in the diagnosis, but not pathognomonic.
- Delay in diagnosis is common due to the protracted clinical course and difficulty of isolating the organism from culture
- The diagnosis may be confirmed with acid-fast stain or culture on Lowenstein-Jensen medium.
- Lack of response to conventional antibiotic therapy is usually a clue to the diagnosis of this unusual keratitis
 - Triple therapy Tx recommended (FLO, Fortified Amikacin and Clithromycin)



Poll Question

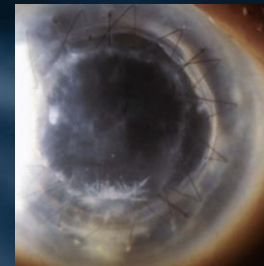
5. Which microbe creates a Cracked windshield appearance to the cornea?



- A. Pseudomonas
- B. Nocardia
- C. Non-Tuberculosis Mycobacterium
- D. Fungal Infections
- E. Infectious Crystalline Keratopathy

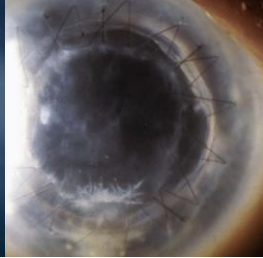
Infectious crystalline keratopathy

- Characterized by minimal stromal inflammation with fine needle-like extensions in the corneal stroma, resembling a snowflake
- Several causes
 - most common causative organism is alpha-hemolytic streptococci and Streptococcus Viridans
 - Others include:
 - Streptococcus pneumoniae, Staphylococcus epidermidis, Peptostreptococcus, Haemophilus, agrophilus, Pseudomonas, Klebsiella, Citrobacter, Enterobacter, and Serratia marcescens, Mycobacterium fortuitum, Candida albicans, and other fungi
- Organisms with low virulence invade the cornea and replicate, but incite little host response.
- Colonies of bacteria grow into the cornea through interlamellar spaces, so the keratitis can be seen as linear, crystal-like structures in the stroma.
- Unlike other bacterial corneal ulcers, infectious crystalline keratopathy usually has an intact epithelium and is not associated with severe stromal inflammation.
- Risk factors include prior surgery, particularly after penetrating keratoplasty, wearing a therapeutic contact lens, chronic use of topical corticosteroids and topical anesthetic abuse.
- Definitive diagnosis requires isolation of the causative organisms. To obtain an adequate corneal specimen for diagnosis of this type of keratitis



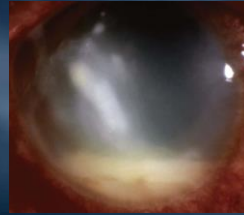
Poll Question

2. Which microbe creates a Snow flake arborizing (branching) pattern?



- A. Pseudomonas
- B. Nocardia
- C. Non-Tuberculosis Mycobacterium
- D. Fungal Infections
- E. Infectious Crystalline Keratopathy

Rapid Tissue Destruction

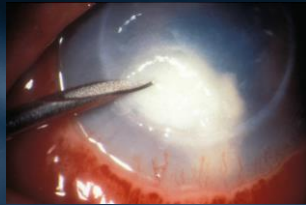


Bacteria that cause rapid tissue destruction

- Pseudomonas
- Staph
 - Staph Aureus (MRSA and Non-MRSA)
- Strep
 - Strep Pneumoniae
 - B hemolytic Strep
- Gonococcus

When to culture

- 1-2-3 Rule
 - 1 mm from Central VA
 - 2 or more lesions on cornea
 - 3 mm in size or greater
- 4-5
 - Anything post surgical (LVC, PK)
 - Not responding to conventional Tx



Management

- Intensive topical antimicrobials
 - Antibiotics, antifungals and antiseptics
- Two phases of MK management:
 1. First Phase Goal
 - Achieve ocular sterilization
 2. Second Phase Goal
 - Promote corneal healing
 - Decrease inflammation, full re-epithelization, and make eye comfortable

Management

- Topical Corticosteroids
 - Potential benefit of reducing corneal scarring and improved patient comfort, balanced against excessive suppression of immune response and resultant potentiation of infection
 - long been a subject of debate
 - Deleterious in cases of fungal and Acanthamoeba keratitis
 - Increases pathogenicity in AK

Management

- SCUT – Steroids for Corneal Ulcer Trial
 - Double masked clinical trial comparing outcomes of bacterial keratitis with topical 0.5% moxifloxacin and 1% pred phosphate vs placebo
 - All subjects had 48h of moxi before randomization
 - Timing of steroid initiation was at discretion of provider (48h >4d)
 - At 3 months, found no diff in BCVA or epi healing
 - Actually worsens Nocardia infected corneas – enlargement of infiltrate

Srinivasan M, Mascarenhas J, Rajaraman R, et al. Corticosteroids for bacterial keratitis: the Steroids for Corneal Ulcers Trial (SCUT). Arch Ophthalmol 2012;130:143–50.

Management

- SCUT Subgroup analysis
 - Showed benefit of steroid in pt with severe keratitis
 - Central corneal ulcers of, significant decrease in vision at presentation
 - Susceptibility of Nocardia strain to Moxi varied greatly by strain
 - N pneumonia 45%; N farcinica 100%
 - Amikacin was found to be a better choice for Tx, with 98% of SCUT strains showing susceptibility to it.
 - Those who initiated steroids within 2-3 days of AB therapy had 1-line better VA at 3 months than placebo
 - Those >4 days showed minimal difference

Management

- Corneal Collagen Cross-linking
 - photoactivated chromophore for infectious keratitis - PACK-CXL
- Intrastromal antimicrobials
 - ? Efficacy, small study showed worsened VA due to scarring
- Amniotic membrane transplantation
 - Contains growth factors to support growth of progenitor cells
 - Contains cytokines and protease inhibitors to inhibit inflammatory cells
 - Contains collagen, laminin and fibronectin aiding in re-epithelization
- Novel Therapies
 - Iontophoresis – small electrical charge to transfer drug
 - CL impregnated with drugs
 - Bovine collagen shields
 - Yag and Argon Lasers

Fungal Keratitis

Fungal Keratitis

- Fungal keratitis is relatively uncommon
 - 6-20% of all microbial keratitis
 - Makes up 5% of all CL related infections
- 2005 outbreak of Fusarium keratitis was linked to MPS
 - B+L ReNu with MoistureLoc
- CDC found cases starting June 2005, peaking April 2006
 - 164 confirmed cases over 33 states and 1 US territory
 - 71% reported using MoistureLoc
 - Withdrawn from US Market on April 13, 2006
 - World market on May 15, 2006
 - Post-recall surveillance found sharp decline of Fusarium within 2 mo of outbreak

Fungal Keratitis

- Despite resolution of outbreak, the number of contact lens related fungal infections are still on the rise
 - Mass Eye and Ear study (excluded data from outbreak)
 - 19 cases from 1999-2002
 - 40 cases from 2004-2007
- Increased to the point that the proportion of infections related to CL wear, has supplanted trauma as the most common cause of fungal keratitis
 - Despite Fusarium levels going back to baseline after outbreak, non-Fusarium increased in both CL and non-CL wearers

Jurkunas U, Behlau J, Colby K. Fungal keratitis: changing pathogens and risk factors. *Cornea* 2009; 28:638-643.

Fungal Keratitis

- Duke University study showed two interesting trends
 1. Significantly higher prevalence of mixed bacterial-fungal corneal infections (38%)
 - Coagulase negative staphylococcus was identified to be the most common organism assoc with co-infection
 2. Significantly higher number of cases (37%) required surgical intervention
 - Indicating increased severity of fungal infections

Ho JW, Fernandez MM, Reborg RA, et al. Microbiological profiles of fungal keratitis: a 10-year study at a tertiary referral center. *J Ophthalmic Inflamm Infect* 2016; 6:5; DOI: 10.1186/s12348-016-0071-6

Fungal Keratitis

- Represents one of the most difficult forms of microbial keratitis to diagnose and treat
- Difficulties arise in making the correct diagnosis, establishing the clinical characteristics of fungal keratitis, and obtaining confirmation from the microbiology laboratory
- Other problems relate to treatment:
 - It is difficult to obtain topical antifungal preparations
 - Tx's do not work as effectively as antibiotics for bacterial infections
 - Infection is often more advanced because of delays in Dx

Fungal Keratitis

- The increasing laboratory capability for recovery of fungi from infected corneas has increased our awareness of fungal keratitis
- There has been an increase in the number of reported cases of fungal keratitis
 - Despite resolution of Fusarium outbreak, levels of non-Fusarium are on the rise (no additional risk factors have been identified)
- The increasing use of broad-spectrum topical antibiotics may provide a non-competitive environment for fungi to grow
- use of topical corticosteroid enhances the growth of fungi while suppressing host immune response
- There has also been an increase in fungal keratitis related to the use of soft contact lenses.
 - Contact lenses 20-35%
 - Trauma 10-20%

Fungal Keratitis

- Ophthalmic fungal isolates includes four diagnostic/laboratory groups:
 - Yeasts: include Candida spp (has geographic tendencies)
 - Filamentous septated fungi:
 - Nonpigmented hyphae
 - Fusarium spp. (most common in US)
 - Aspergillus spp.(most common worldwide)
 - Pigmented hyphae (Alternaria spp. and Curvularia spp.)
 - Filamentous nonseptated fungi, which include Mucor spp.; and others
- Gain access into the stroma from a defect in the epithelium (CL wear or trauma)
- If gains access to anterior chamber, difficult to eliminate

Risk factors for development of fungal keratitis

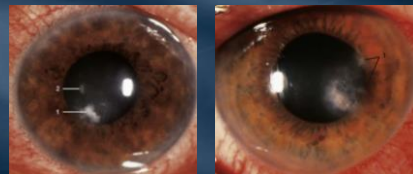
- Poor CL habits, Risky behaviors
- Trauma (including contact lenses)
- Topical medications (corticosteroids and others)
- Corneal surgery (penetrating keratoplasty, LASIK, radial keratotomy)
- Chronic keratitis (herpes simplex, herpes zoster, vernal/allergic conjunctivitis)

Fungal Keratitis

- The symptoms of fungal keratitis do not present as acutely as with other forms of microbial keratitis (indolent growth).
 - may report the initial symptom of a foreign body sensation for several days with a slow onset of increasing pain.
- The most frequently encountered external and slit lamp signs of fungal keratitis are commonly seen in other forms of microbial keratitis and include suppuration, conjunctival injection, epithelial defect, stromal infiltration, and anterior chamber reaction or hypopyon.
- Can also create a ring infiltrate

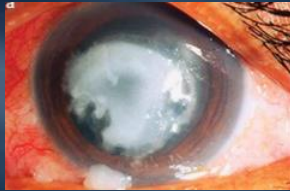
Fungal Keratitis

- Some findings such as elevated areas, hyphate (branching) ulcers, irregular feathery margins, a dry rough texture, and satellite lesions can be helpful in suggesting filamentous fungi.



Poll Question

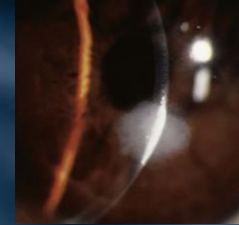4. Which microbe creates a dry rough appearance to cornea



- A. Pseudomonas
- B. Nocardia
- C. Non-Tuberculosis Mycobacterium
- D. Fungal Infections
- E. Infectious Crystalline Keratopathy

Fungal Keratitis

- The presence of an intact epithelium with a deep stromal infiltrate may also be found in fungal keratitis
 - Advances despite intact epi



Fungal Keratitis

- Despite these descriptive findings, studies to assess the clinical manifestations of suppurative (bacterial) versus fungal keratitis have demonstrated that it was not possible to differentiate clinically between bacterial and fungal keratitis, especially in cases where yeasts are the infecting fungi
- Therefore Laboratory diagnosis is essential
 - Fungi also have been cultured from topically applied medications, cosmetics, contact lenses, and their storage and cleaning solutions in patients with fungal keratitis.
 - These items should be obtained from the patient at the initial visit. Cultures and smears can be obtained to increase the chances of identifying the causative organism.

Fungal Keratitis

- The Gram and Giemsa stains are the most common initial stains used for the rapid identification of fungi
 - Initial studies reported the detection of hyphal fragments of filamentous fungi, blastospores, or pseudohyphae of yeasts in 78% of smears of fungal keratitis
- Culture media for suspected fungal keratitis should include the same culture media used for a general infectious keratitis work-up
 - These include sheep blood agar, chocolate agar, Sabouraud's dextrose agar, and thioglycollate broth
- Positive cultures should be expected in 90% of cases
 - Initial growth occurs within 72 hours in 83% of cultures
 - 1 week in 97% of cultures
- Other less widely used methods for the identification of fungi include Confocal Microscopy, immunofluorescence staining, electron microscopy, and polymerase chain reaction (PCR)

Fungal Keratitis

- Along with assisting in a diagnosis, scraping also provides for initial debridement of organisms and of epithelium, which can improve penetration of the antifungal medication.
- Clinically, commercially available natamycin 5% suspension is the initial drug of choice for fungal keratitis
- If worsening of the keratitis is observed on topical natamycin, topical amphotericin B 0.15% can be substituted in cases of Candida spp. keratitis and Aspergillus keratitis
- An oral or topical azole can be substituted or added in cases Fusarium spp. Keratitis
- The length of time required for topical treatment has not been firmly established clinically or experimentally.
 - Average of 30 days of treatment for Fusarium keratitis with natamycin
 - The inflammatory response from this toxicity can be confused with persistent infection. If toxicity is suspected and if adequate treatment has been given for at least 4 to 6 weeks, treatment should be discontinued and the patient carefully observed for evidence of recurrence

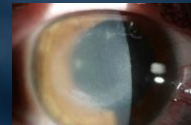
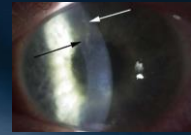
Fungal Keratitis

- Topical corticosteroids in the treatment of fungal keratitis must be approached cautiously
 - O'Day et al. reported that the efficacy of amphotericin B appeared unaffected when used in conjunction with topical 1% prednisolone acetate in a rabbit model of Candida spp. keratitis
 - Topical corticosteroid worsened the disease when given alone and adversely influenced the efficacy of natamycin, flucytosine, and miconazole when given in combination
- Recommend not consider topical steroids until after at least 2 weeks of antifungal treatment and clear clinical evidence of control of the infection
- Careful follow-up is required to ensure that improvement is taking place. The steroid drop is used in conjunction with the topical antifungal and never without
 - Usually, steroid treatment is carried on for 2 to 3 weeks

Acanthamoeba Keratitis

Acanthamoeba keratitis

- Free-living amoeba found ubiquitously in water and soil
 - Typically feeds on blue-green algae, bacteria and fungi
 - Stromal keratocytes
- Uncommon
 - Incidence:
 - 1.65-2.01 cases per million US
 - 17-21 cases per million in UK
- Primarily contact lens related
 - Approx 90% of reported cases
 - Poor CL hygiene and exposure to contaminated water
- Classic presentation included radial keratoneuritis, a corneal ring infiltrate and/or disproportionate, incapacitating pain
 - Most patients present with less characteristic signs and symptoms frequently contributing to diagnostic delay



Acanthamoeba keratitis

- 2006 outbreak was found to be associated with Advanced Medical Optics Complete MoisturePlus
 - Despite withdrawal from market on May 29, 2007, levels of AK did not decline back to baseline levels
- Second CDC outbreak between 2008-2011 in 28 states
 - No identifiable risk factors
 - When different MPS systems tested, ALL were found to be equally ineffective in killing cysts
 - the risk is 10x greater than before 2004

Acanthamoeba keratitis

- Commonly mistaken for non-infectious as well as bacterial, fungal, or viral causes of chronic keratitis
 - the amoebic infection is resistant to commonly utilized ophthalmic antimicrobial agents, but may become transiently asymptomatic with the use of corticosteroids.
- Excellent outcomes are probable when the infection is diagnosed and treatment initiated before deep infiltration.
- Medical cure requires the specific use of biguanides alone or in combination with a diamidine for weeks to months or longer.
- Clinical resistance does occur and may require more aggressive medical or surgical therapy.

Acanthamoeba keratitis

- They present in two distinct states
 - as a more vulnerable, freely mobile trophozoite
 - double-walled cyst
 - extremely resistant to extremes of temperature, desiccation, irradiation, antimicrobial agents, and other changes in environment
- When challenged, trophozoites can encyst rapidly, within hours, preserving the ability to produce viable trophozoites decades later.

Acanthamoeba keratitis

- In both soft and rigid lens wearers, trauma, swimming in lenses, and noncompliance with contact lens disinfection systems are associated with an increased risk of Acanthamoeba keratitis
 - First generation SIHI have greatest risk
- Other hygiene-related variables include contact lens wear during hot tub use as well as rinsing lenses or cases in nonsterile water
 - 1980's outbreak due to homemade saline
- While no specific soft lens type has yet been associated with Acanthamoeba keratitis, specific contact lens care systems have been associated with greater risk
- The systems most effective against both forms of the amoeba are heat and hydrogen peroxide disinfection, specifically the two-step type which ensures extended disinfectant exposure time prior to neutralization

Acanthamoeba keratitis

- Cysts are highly resistant to chlorine and most current multipurpose solutions (MPS)
 - use of one-step hydrogen peroxide systems, chlorine-based disinfection, and, most recently, AMO Complete MoisturePlus, an MPS, have been associated with an increased risk of Acanthamoeba keratitis
- Despite this specific association, it should be noted that nearly 50% of patients in the recent US outbreak were using other disinfectants, mostly other MPS's, suggesting that these systems may also present additional risk
- Similarly, no wearing schedule, e.g. overnight wear or frequent replacement, has yet been associated with Acanthamoeba keratitis, but daily replacement lenses may be protective since solutions and repeated handling are not involved in their care.

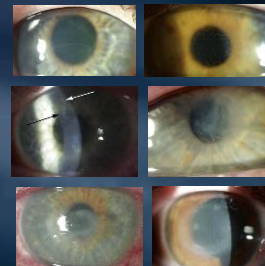
Acanthamoeba keratitis

- Acanthamoeba keratitis is often recognized at first presentation only when accompanied by a high index of clinical suspicion.
- Any age may be affected, and no sex predilection has been noted,
 - although a larger number of contact lens wearers are female.
- Acanthamoeba keratitis is bilateral in 7–11% of patients.
- The distribution of other clinical features described in most large series is likely biased toward advanced stages of disease, as would be expected from tertiary care facilities.
- The spectrum of signs and symptoms, therefore, represents various stages in its chronic, indolent course rather than distinct manifestations of disease.

Acanthamoeba keratitis

- A strong suspicion for Acanthamoeba infection should, therefore, include any patient with the risk factors:
 - primarily contact lens wear with or without significant noncompliance,
 - significant water exposure or
 - contaminated trauma combined with the clinical features of any known presentation of disease.
- Other commonly reported characteristics,
 - including a history of chronicity, multiple physician referrals, culture-negative scrapings, resistance to antimicrobial agents (bacterial, fungal, and viral), and previous corticosteroid use, are related to the indolent nature of the disease and misdiagnosis or delayed diagnosis rather than being an integral feature of the disease.
 - Accordingly, initial presentation may be virtually asymptomatic or manifest as a nonspecific foreign body sensation, photophobia, sometimes escalating to severe, intractable pain with visual acuity similarly unpredictable in the early stages.

Acanthamoeba keratitis



- Progressive disease
 - Epithelitis
 - Cystic dendritiform epitheliopathy
 - Perineural infiltration
 - Stromal Keratitis
 - Ring infiltrate
 - Corneal thinning and perforation
 - Sterile hypopyon

From Tu EY, Joslin CE, Sugar J, Shoff ME, Botton GC. Prognostic factors affecting visual outcome in Acanthamoeba keratitis. Ophthalmology. 2006;115(11):1996–2003.

Acanthamoeba keratitis

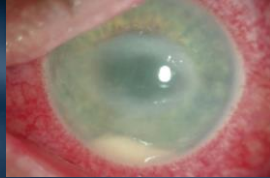- Epithelitis represents a predominantly epithelial infestation which may present with a mild foreign body sensation ranging to moderate pain and mild loss of visual acuity
 - Its flat, diffuse microcystic form exhibits relative perilimbal sparing and may be confused with dry eye or contact lens-associated surface toxicity
- Epithelial ridges, whorls, and pseudodendrites may be commonly confused with epithelial herpetic keratitis as evidenced by the high proportion of antiviral use in patients ultimately diagnosed with Acanthamoeba keratitis
 - Corneal sensation in these early stages may be paradoxically decreased, further mimicking herpetic disease
- The disease may remain restricted to the epithelium, sometimes indefinitely. Simple debridement without other medical intervention has been rarely reported to be curative at this stage
- Stromal invasion may take the form of anterior stromal disease which is characterized by shallow stromal excavation and/or localized stromal infiltration, with or without an overlying epithelial defect, involving the anterior third of the stroma. These patients may also have moderate to more significant pain, but usually exhibit less global inflammation than more advanced stages of disease
- Visual acuity is dependent on the location of stromal lesion and inflammatory response

Acanthamoeba keratitis

- The most characteristic signs and symptoms include severe, incapacitating pain, the presence of a ring infiltrate, and radial keratoneuritis
- Radial keratoneuritis, representing amoebic migration along the corneal nerves and the host immune response, occurs in mid or deep stroma, beginning centrally or paracentrally and extending toward the limbus. It may accompany any stage of the disease.
 - Although largely pathognomonic for Acanthamoeba keratitis, it has also been described in Pseudomonas keratitis. The often disproportionate pain, usually more severe than fungal keratitis, in advanced disease invariably includes extreme photophobia related possibly to its neurotrophic nature, its ability to synthesize certain prostaglandins, and the host's reactive immune response
- The visible ring infiltrate represents an immune hypersensitivity response which may be related or unrelated to the viability of the organisms.
 - Prior to the formation of a defined ring, herpetic disciform keratitis, other forms of interstitial keratitis, and anesthetic abuse may also mimic this appearance. Accurate diagnosis with these signs of infection is probable, but, with the exception of radial keratoneuritis, represents advanced disease which has been shown to carry with it a poorer prognosis for both medical cure and visual recovery

Acanthamoeba keratitis

- Extracorneal manifestations of Acanthamoeba include limbitis, scleritis, uveitis, as well as eyelid abnormalities including edema and dacryoadenitis.
- Most of these are thought to be inflammatory rather than infectious, without evident organisms in the region of inflammation, but choroidal and intraocular recovery of organisms has been rarely reported.
- A significant proportion of Acanthamoeba keratitis patients have been found to have co-infections involving a second bacterial, fungal, or viral agent.



Acanthamoeba keratitis

- Treatment
 - Biguanides
 - Cystical
 - Polyhexymethylene Biguanide (PHMB) 0.02%
 - Chlorhexadine 0.02%
 - Diamides
 - Active only against Trophozites
 - Brolene (propamidine isethionate)
 - Hexamidine
- Treatment should persist for months after resolution to ensure cysts are eradicated

Herpetic Keratitis

Background

- It is estimated that 70–90% of American adults have antibodies to HSV-1 and/or HSV-2 and about 25% of these individuals have clinical symptoms upon routine clinical inquiry, with HSV-1 being responsible for >90% of ocular HSV infections.
- In the U.S., approximately 50,000 people suffer recurrent ocular HSV episodes annually, requiring doctor visits, medication, and in severe cases, corneal transplants.
- US incidence is 500,000 and the global incidence of HSV keratitis is roughly 10 million, including 40,000 new cases of severe monocular visual impairment or blindness each year.

Background

- Infection leads to corneal scarring and neovascularization, permanent endothelial dysfunction and corneal edema, secondary glaucoma and cataract.
- Prognosis can be limited following PK due to recurrent inflammation and highly vascularized corneas.

HSV Infections

- Blepharitis
- Conjunctivitis
- Scleritis
- Keratitis
- Neurotrophic Keratopathy
- Stromal Disease
 - Necrotizing
 - Immune / interstitial
- Endothelitis
 - Disciform
 - Diffuse
 - Linear
- Iridocyclitis
- Trabeculitis

HSV Keratitis

- One of most challenging entities confronting clinicians due to variety of Clinical Manifestations
- Infectious Epithelial Keratitis
 - Cornea Vesicles
 - Dendritic Ulcer
 - Geographic Ulcer
 - Marginal Ulcer
- Neurotrophic Keratopathy
- Stromal Keratitis
 - Necrotizing stromal keratitis
 - Immune stromal (interstitial) keratitis
- Endotheliitis
 - Disciform
 - Diffuse
 - Linear

HSV Keratitis

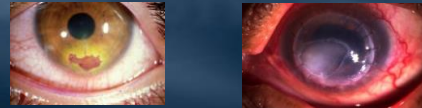
- One of most challenging entities confronting clinicians due to variety of nomenclatures
- Infectious Epithelial Keratitis
 - Aka – Dendrite, Herpetic epithelial keratitis,
- Neurotrophic Keratopathy
 - Aka – Trophic / neurotrophic ulcer, metaherpetic, indolent ulcer
- Necrotizing stromal
 - Aka – viral necrotizing, ulcerating IK
- Immune stromal keratitis
 - Aka – interstitial keratitis, disciform keratitis, stromal keratitis, non-necrotizing, immune ring wessely ring
- Endotheliitis
 - Aka – Disciform keratitis / edema, keratouveitis, central endotheliitis, disciform disease w endotheliitis

HSV Keratitis

- Typically unilateral
 - Bilateral approximately 3% of cases
 - 40% of those have Hx of atopy
- Red eye, Pain, irritation, epiphora, +/- decreased VA

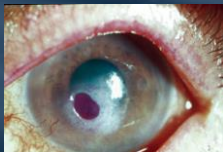HSV Neurotrophic Keratopathy

- Many names
 - Trophic / neurotrophic ulcer, metaherpetic, indolent ulcer
- Unique bec neither immune or infectious, ie no live virus
- Arises from impaired corneal innervation in combination with decreased tear secretion
- Exacerbated by chronic use of topical medications, esp antivirals
- Irregular corneal surface, lack of normal luster



HSV Neurotrophic Keratopathy

- Trophic / Epi defect typically oval in shape w smooth borders
 - Persistent defect leads to stromal ulceration
 - With risk of stromal scarring, neovascularization, necrosis, perforation and secondary bacterial infection



HSV Neurotrophic Keratopathy Management

- Therapy aimed at decreased exposure to toxic substances while increasing lubrication
 - D/c all unnecessary topical meds, esp antivirals
 - Heavy non-preserved tears
- Gentle debridement of boggy epithelium at ulcer edge
- If chronic inflammation seen at base of ulcer then topical corticosteroid
- Therapeutic soft contact lens and topical AB
- Sutureless Amniotic membrane
- Tarsorrhaphy
 - Tape, sutured, botulinum toxin
- Conjunctival flaps

HSV Stromal Disease

- Stromal disease accounts for 2% of initial episodes but 20-48% of recurrent disease
- Commonly confused and poorly categorized
- Stroma can be affected either primarily or secondarily
 - Secondary causes such as infectious epithelial keratitis, neurotrophic keratopathy or endotheliitis should direct its tx towards those layers
- Primary involvement includes Necrotizing Stromal keratitis and Immune Stromal keratitis

HSV - Immune Stromal Keratitis

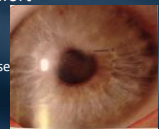
- Synonymous with interstitial keratitis
 - Confusing terminology
 - Stromal neovascularization w inflammation??
 - Posterior neovascularization only??
 - Syphilitic keratitis??
 - Refers to any inflammatory condition of the stroma that has an immunologic etiology
 - not restricted to:
 - Presence or absence of neo
 - Depth of stromal inflammation
 - Etiology of inflammation

HSV - Immune Stromal Keratitis

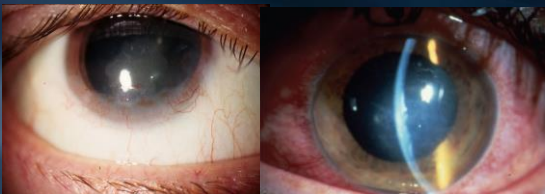- Common chronic recurrent manifestation
- 20% of all Ocular HSV
- After infectious epithelial keratitis
 - 21% within 2 years
 - 26-48% within 7 years
- Not live virus but retained viral antigen within stroma
 - Triggers an antigen-antibody-complement (AAC) cascade resulting in stromal inflamm
 - T-cell mediated autoimmune response

HSV - Immune Stromal Keratitis

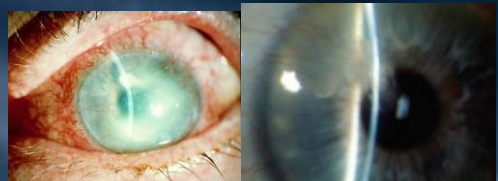
- Underlying stromal inflammation with intact epithelium
- Can lead to severe scarring and dec vision
 - Vision loss from immune stromal keratitis scarring accounts for 3% of all PK's performed
- Patients present in pain and discomfort
- Can take on several forms
 - Punctate stromal opacities and haze
 - Pattern may be focal, multifocal or diffuse
 - Often has AC rxn and ciliary flush
 - Stromal edema



HSV - Immune Stromal Keratitis

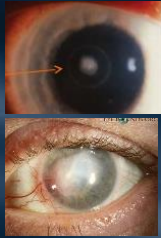

HSV - Immune Stromal Keratitis



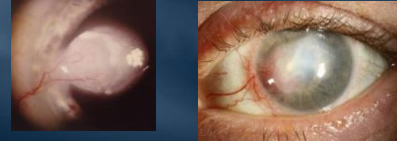HSV - Immune Stromal Keratitis

- Immune ring or Wessely ring
 - AAC precipitate that forms full or incomplete ring found in mid stroma
 - May have one or multiple rings
- Stromal Neovascularization
 - May occur at any level
 - Can occur rapidly w multiple fronds
 - Sectoral or diffuse
 - Aggressive tx of inflammation can result in complete resolution of vessels
 - Ghost vessels common



HSV - Immune Stromal Keratitis

- Lipid Keratopathy can follow neovascularization
 - Neo leaks lipid into stroma
 - Leads to further scarring and loss of vision
- Permanent neovascularization decreases the success rate of PK due to inc risk of rejection



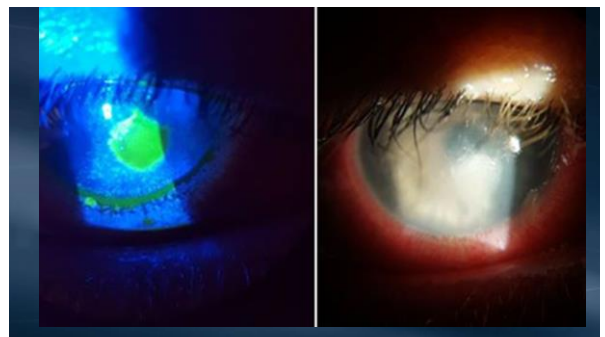HSV - Immune Stromal Keratitis Management

- Corticosteroids needed in tx pt with immune mediated disease
- High initial dose, q2h, to control inflammm
 - Avoid rapid taper
 - Customize to the amount of inflammation
 - Controversy with HEDS
 - Tx longer than 10 weeks
 - "Flare Dose"
- Match one to one dosing with concurrent antiviral
- Prophylaxis
 - 400mg Acyclovir BID PO long term

Case Presentation

Case presentation

30 yowm presents today, contact lens wearer (calls at closing, I stay an hour as the patient needed a ride from a common friend of ours and the image and symptoms our friend texted me is alarming) with HIL. PHIL VA. THE HISTORY BELOW IS PATIENT REPORTED, NOT INDICTING ANOTHER O.D., as I hope this wasn't their treatment plan, patients lie, etc. Reported to another O.D. on Thursday who diagnosed an abrasion and started him on unknown antibiotic and (pt says) directed him to continue wearing his contact lens (that is where I hope something was lost in translation: bandage on a CL wearer, I hope no one is doing this). Pt calls the other office on Friday, says he told them he was in 10/10 pain. The O.D. tells him to remove the lens and starts him on gatifloxacin q1h. Common friend brings him to me. I interrogate him on what he did, and after much questioning he finally admitted to leaving a lens Thursday morning at a work site, found a "backup" lens in a case in his work bag. This lens is 2 to 3 months old (meaning 6x). I get the best local cornea OMD on the phone. He sees the pic, we agree he needs to culture, and meets the patient. The OMD leaves his kids with his wife, and also leaves a brisket on the smoker. We agree to get him on natascyn until the culture comes back. Hopefully the eye ends up better than the brisket, which was sadly overcooked, a severe crime down here. :(((



Conclusion

- Many causes of microbial keratitis
- Identify the risk factors for ocular infection
- Assess the distinctive corneal findings



Thank you



Please feel free to contact us:

Nicholas Colatrella, OD, FAAO, Dipl AAO, ABO, ABCMO
NColatrella@pineconevisioncenter.com

Jeffrey Varanelli, OD, FAAO, Dipl ABO, ABCMO
SECJRVOD@gmail.com